

Case Report

Machete-Cut Maxillofacial Injuries in Civilian Setting: Case Series from a Tertiary Health Care Facility in Sokoto, Northwestern Nigeria.

Bala M¹, Braimah RO², Taiwo AO³, Sadeeq FA⁴, Umar SY⁵, Olayemi LA⁶, Sorunke HA⁷

^{1,4,6,7}BDS Department of Dental and Maxillofacial Surgery, Usmanu Danfodiyo University Teaching Hospital (UDUTH) PMB 2370, Sokoto, Nigeria

^{2,3}BChD, FWACS, FAOCMF Department of Dental and Maxillofacial Surgery, Usmanu Danfodiyo University Teaching Hospital (UDUTH) PMB 2370, Sokoto, Nigeria

⁵MBBS, FWACS Department of ENT, Usmanu Danfodiyo University Teaching Hospital (UDUTH) PMB 2370, Sokoto, Nigeria

Received: 20 August, 2022 Accepted: 10 September, 2022 Published: 15 September 2022

Abstract:

Machete-cut injuries are not uncommon and are usually associated with severe soft tissue disruption and unusual bone fractures. This could result into a potentially life-threatening injuries that could pose challenges in management. Six patients seen and managed for machete-cut injuries over a period of 2years (From July 2020 to August 2022) at the Dental and Maxillofacial surgery unit of Usmanu Danfodiyo University Teaching Hospital Sokoto were presented. All the victims were males sustaining varying degrees of soft and hard tissue injuries, with no tissue avulsion. Four (4) cases of the series were treated under local anaesthesia and conscious sedation while the remaining two (2) cases were done under general anaesthesia. Open reduction and internal fixation were done in four (4) of the cases, splinting in one (1) case and only soft tissue repair in one (1) case. Facial nerve palsy, mental and buccal nerve anaesthesia were the observed nerve injuries. Early presentation, careful assessment of the injuries and meticulous planning will reduce morbidity and mortality associated with such injuries. There is need for preventive mechanisms such as providing education as well as reducing rate of unemployment in our society.

Keywords: Injury, Machete-cut, Maxillofacial, Surgery

Introduction

Maxillofacial injuries have multiple etiological factors; including road traffic accident, falls, assaults and animal attack.¹ Assault-related maxillofacial injuries are becoming more and more frequent and constitute one of the most important cause of fractures to the craniofacial bones.² This is likely because of the prominence and easy access to the face in violence situations. Increase in violence and criminal activities due to high rate of unemployment, political and economic factors especially in underdeveloped and developing nations have been suggested to be the reasons for the increase in the hike of assault related injuries.³

Several instruments including machete, knife, axe, wood, iron rod as well as human teeth (in human bite cases) have been used by the assailants in causing injuries to the maxillofacial region.² Machete is a knife-like instrument which is long with thick back, broad bladed with sharp edge and usually have curved or straight end. It is attached to a handle made up of wood, leather or plastic for comfort gripping.⁴ Machetes are widely used domestically in our environment for clearing of grasses and, they are sometimes kept for self-

defense and family protection because of their easy acquisition and access. Machetes are also used for farming activities such as bush/farm clearing and harvesting. The Matchet injuries to the maxillofacial region have been reported in the literature.^{3, 4} These injuries could range from simple lacerations to complicated maxillofacial compound fractures. Involvement of important vital structures such as the facial nerve, salivary gland and ducts could be some of the dreaded complications. The vascular richness of the face could pose the affected patients to serious life-threatening bleeding. Such situations are associated with appreciable morbidity and mortality and may affect the functional, esthetic and psychological well-being of the affected individual.⁵

Because of the unusual pattern of such injuries, their management may be challenging. However, with careful and proper systematic approach, those challenges can be overcome. The focus of the surgeons should always be concentrated towards restoring functions, esthetic as well as the psychological well-being of the victims.

Assaults injuries, specifically machete-cut to the maxillofacial region were believed to be under-reported.^{3, 4} This report aims to present the occurrence and unusual pattern of machete-cut

maxillofacial injuries and highlight the important aspect in their management.

Case Report

A total of six (6) victims of machete cut injuries were seen and managed during the 2-year study period and all were included in the analysis. Clinical data including Patients' age, sex, occupation, sites of injuries and tissues affected, anaesthetic techniques, surgical procedure performed and complications were all recorded (Table 1). All the victims in this series were males in the age range of 19-34 years with mean±SD of 27.7±5.5years. All patients were from similar environment and three (50%) of the victims are farmers, 2(33.3%) businessmen and only 1(16%) student. The assailants were unknown in five of the six (6) case series. There was history of profuse bleeding from the multiple injured sites in two (2) of the victims though the quantity of lost blood could not be ascertained. One (1) patient had history of blood transfusion with 2 units of blood at the peripheral hospital before referral to our facility. Two (2) patients were said to have received tetanus prophylaxis at the peripheral hospital prior to their presentation to our facility, whereas four (4) of them received the tetanus prophylaxis on their arrival at the trauma center of our institution. However, none of the victims had history of

loss of consciousness, vomiting, urinary or faecal incontinence. None had history of comorbid conditions such as hypertension, diabetes mellitus or bleeding disorders. No history of drug allergy, alcohol consumption or substance abuse recoded in any of the victims. All cases have varying degrees of soft tissue and bone involvement, with no tissue avulsion. Five of the cases have bony involvement and mandible was the commonest craniofacial bone involved. The most extensive injuries occurred in one of the victims and include; soft and hard tissues of the mandible, zygomatico-frontal, infraorbital, auricular and temporomandibular areas, skull vertex and shoulder regions (Figures 1a-1i).

Additional findings include subconjunctival haemorrhage and, reduced hearing in one of the victims which warranted consultation from ENT surgeon and Ophthalmologist. Four (4) of the cases were treated under local anaesthesia and conscious sedation (Figures 2a-2d) as opposed to the remaining two cases which were done under general anaesthesia. ORIF was done in four (4) of the cases, splinting in one (1) case and only soft tissue repair in one (1) case. Facial nerve palsy, mental and buccal nerve anaesthesia were the observed nerve injuries (Figure 3). Patients with nerve injuries were monitored for nerve recover

Table 1: Clinical summary of patients with machete-cut injuries

	Case1	Case2	Case3	Case4	Case5	Case 6
Age(years)	28	32	24	34	29	19
Sex	M	M	M	M	M	M
Occupation	Farming	Farming	Business	Business	Farming	Student
Assailant	Unknown	Unknown	Unknown	Known	Unknown	Known
Maxillofacial region involved	Mandible + ZF region + IO region + Auricular + TMJ region	Mandible	Upper lip + Dentoalveolar segment	Mandible + Middle third	Buccal region	Mandible
Other body part affected	Shoulder + skull vertex	Nil	Right hand fingers	Nil	Nil	Nil
Tissue involved	Soft tissue and bone	Soft tissue and bone	Soft tissue and bone	Soft tissue and bone	Soft tissue only	Soft tissue and bone
Tissue loss	Nil	Nil	Nil	Nil	Nil	Nil
Anaesthetic technique	GA	LA + conscious sedation	LA + conscious sedation	GA	LA + conscious sedation	GA
Surgical procedure done	ORIF + Soft tissue repair	ORIF	Splinting + Suturing	ORIF	Suturing	ORIF
Complication	Facial nerve palsy	Nil	Nil	Mental nerve anaesthesia	Cheek anaesthesia	Nil

ZF= Zygomaticofrontal IO= Infraorbital TMJ= Temporomandibular joint

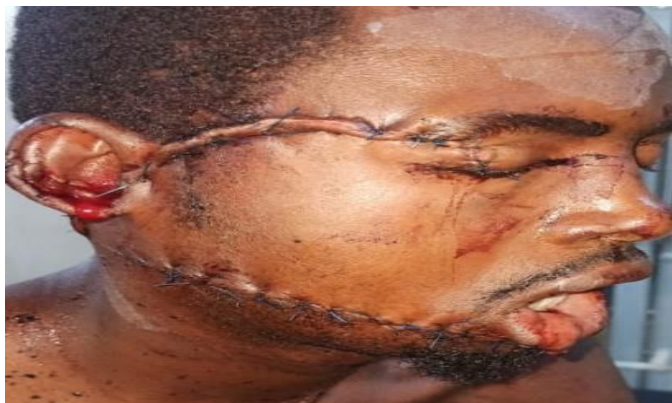

Figure 1a: Patient at presentation with multiple badly sutured lacerations from the peripheral hospital

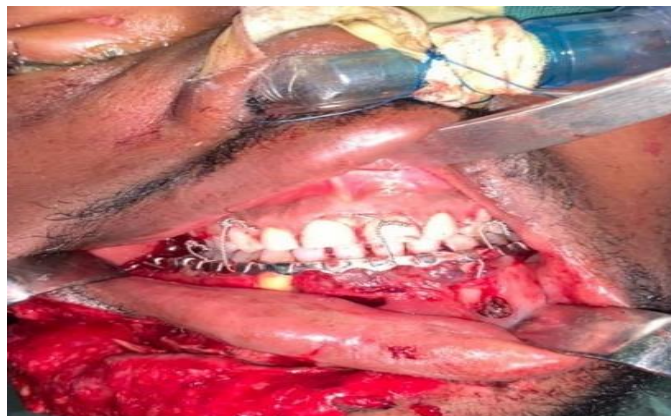

Figure 1f: Intraoperative photograph showing MMF done

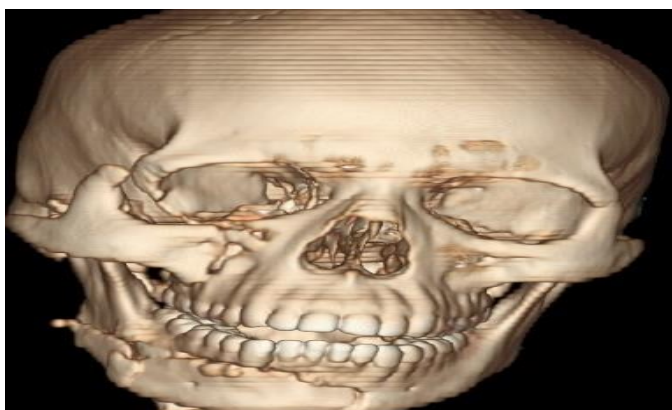

Figure 1b: Anterio-posterior 3D-CT scan showing the sites of fractures

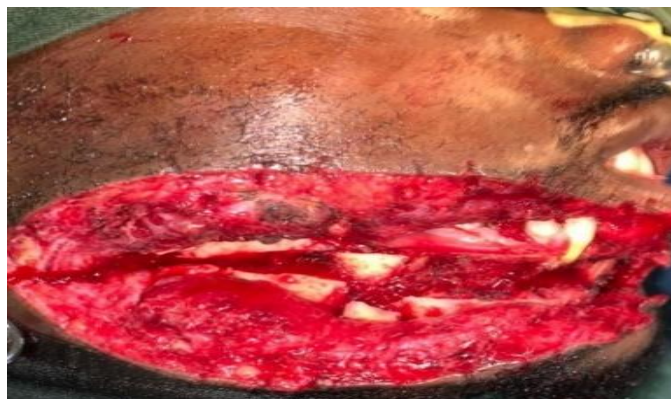

Figure 1g: Intraoperative photograph showing the comminuted mandibular fractures

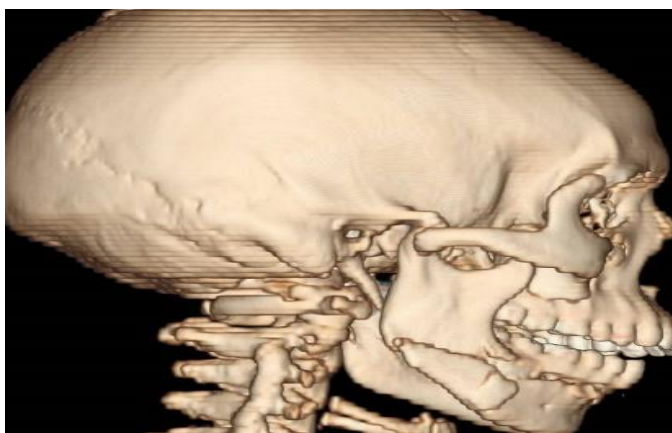


Figure 1c: 3-D CT view showing right temporomandibular joint dislocation

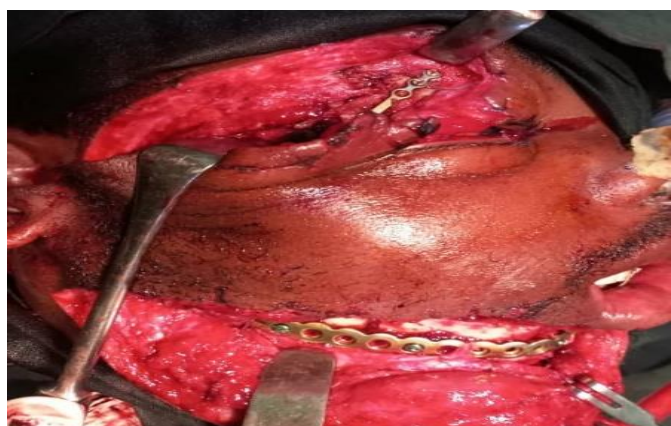

Figure 1h: Intraoperative photograph showing the two sites of fixation (mandible and zygoma)

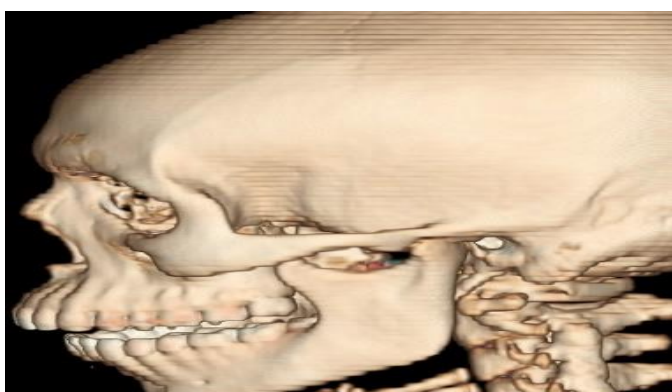

Figure 1d: 3-D CT view showing normal position of the left condyle in the same patient.

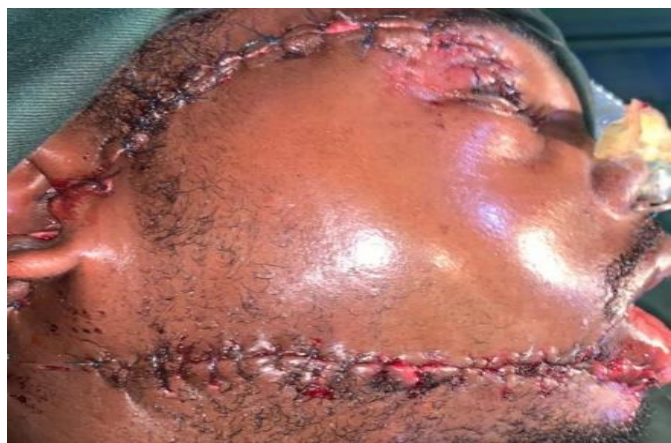

Figure 1i: Intraoperative photograph showing final closure of wound

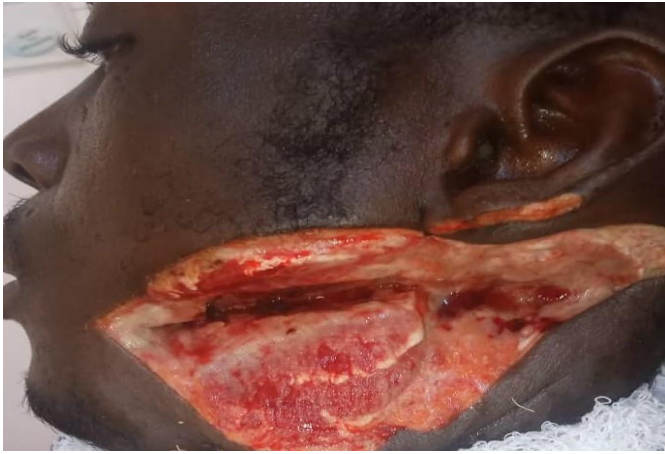

Figure 2a: Clinical photograph of another patient with machete cut injury

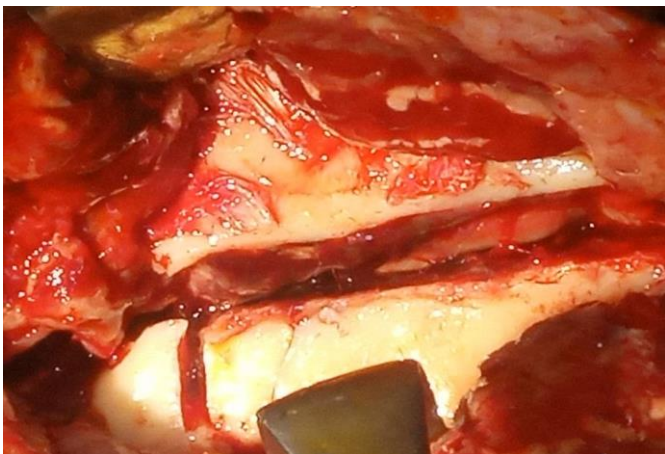


Figure 2b: Clinical photograph showing multiple mandibular fracture

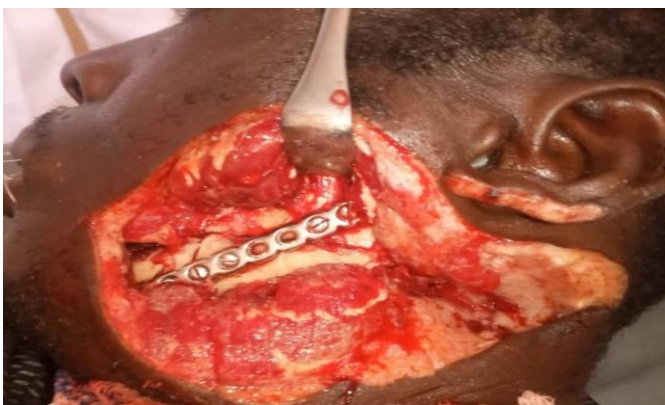

Figure 2c: Intraoperative photograph showing reconstruction plate that was placed under local anesthesia and conscious sedation.

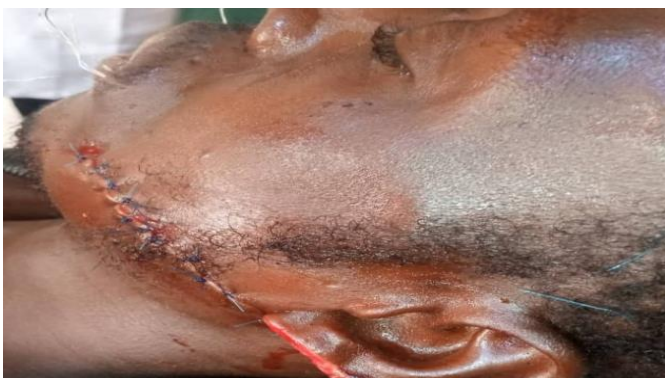

Figure 2d: Immediate postoperative photograph showing final wound closure.

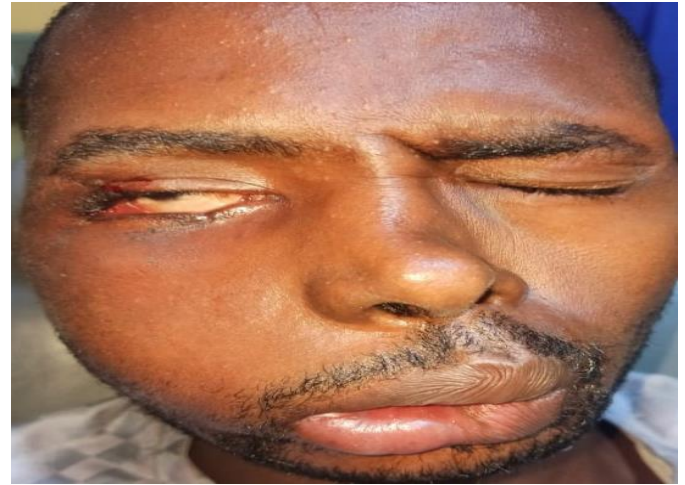

Figure 3: Clinical photograph showing facial nerve palsy post operatively

Discussion

Assault cases of various types are expected occurrences globally.⁶ In Nigeria, different types of etiological factors have been implicated and include; Religious and tribal conflicts, post-election violence, armed robbery and banditry attack among others.³ Attack from unknown assailants is common in our environment, just like the most of the current case report where the motive of the assailants could not be ascertained.⁴ However, it could be a revenge from inter-family rivalry or peer group enmity. Several instruments such as machete, knife, axe, wood, iron rod have been reported to be used by the assailants as weapons for attacks. Machetes have been used as a close-range weapon to attack people during violence and other criminal activities.⁷ Availability, easy access and lack of legislation guiding their acquisition could have been the reason for their use⁵. Machete branded as a farming tool or as a weapon of assault may result in accidental or intentional injuries of varying degrees of severity depending on the mechanism of injury, weight, rigidity and sharpness of the machete⁵.

The true incidence of machete-cut injuries is not available likely due to under-reporting. All the six victims in this report were males in the age range of 19-34 years with mean±SD of 27.7±5.5 years. Chukwudi et al.³ reported five cases of machete-cut in a Nigerian tertiary teaching Hospital in Zaria, Kaduna State among young adult males with age range of 20-30 years and mean age of 24.8 years. Another study by Omoke et al.⁴ in a retrospective study of 74 machete-cut injuries, reported 90.5% male patients and average of 27.9 years. This indicates that young adult male individuals are more prone to be the victims of violence attacks such as the machete cut in these studies.

Machete-cut assault injuries were reported as multiple soft and hard tissue injuries including lacerations and bony fractures that could be seen all over the body though commoner in the head and neck region.⁸ Injuries from machete cuts are regarded as medicolegal especially in homicide cases and are usually presented with multiple cuts mostly situated in the head and neck region with associated defense cuts on the upper extremities⁵. In the current series, no medicolegal nor

homicide reasons were raised because the motive could not be ascertained and the assailants were not apprehended. Machete-cut injuries were seen more frequently on the left side of the face because the majority of population are right-handed and naturally right-handed assailant attack the left side for comfort and proper control of their instruments.⁹ The left side of the face was involved in five of the current case series, suggesting the fact that the majority of assailants may be right-handed.

Nasal and zygomatic regions were the commonest maxillofacial sites reported in the literature.⁷ The site of injury in the current cases series were mostly in the mandibular regions. The surgical treatment was prompt in all the cases and mandibular fractures were multiple in four (4) cases in which 2.5mm reconstruction plate was used (Figure 2c), whereas 1.5mm miniplate was used for other maxillofacial fractures elsewhere (Figure 1h). Dislocation of the right temporomandibular joint was observed in one of the series (Figure 1c). This may likely be due to shouting in search of help. Although, a rare occurrence with machete-cut injuries, temporomandibular joint dislocation secondary to shouting as an etiology have been reported in the literature.^{10, 11}

Facial and mental nerve injuries were involved in one patient, although not treated surgically due to lack of facilities for the surgical repair. The case with facial nerve palsy in this series had delayed onset nerve palsy in which conservative approach was used in the management, thus resulting in functional improvement. Ali et al.¹² in their study of surgical versus conservative facial nerve treatment following temporal bone fractures observed complete recovery in about 90% of patients with delayed onset facial nerve palsy when managed conservatively.

Conclusion

Machete-cut injuries are not uncommon. These injuries are associated with severe soft tissue disruption and unusual bone fractures. Early presentation, careful assessment of the injuries and meticulous planning will reduce morbidity and mortality associated with such injuries. There is need for preventive mechanisms such as providing education as well as reducing rate of unemployment in our society.

Conflict of interest

There is no conflict of interest declared.

References

1. Boffano et. al. Assault related maxillofacial injuries: The result from the European Maxillofacial Trauma (EURMAT) multicenter and prospective collaboration.
2. Olojede ACO, Gbotolorun OM, Ogundana OM, Emeka IC, Emmanuel MM, Oluseye SAB, et al. Pattern of assault-related maxillofacial injuries treated at the general hospital, Lagos, Nigeria. *J West Afr Coll Surg* 2016;6:68–82.

3. Mutto M, Lett R, Lawoko S, Nansamba C, Svanstrom L. Intentional injuries among Ugandan youth: a trauma registry analysis. *Inj Prev* 2010; 16:333–336.
4. Chukwudi OA, Rowland A, Uche O. Machete-cut injuries are occurring in the maxillofacial region in Zaria, Nigeria. *Niger J Clin Pract* 2015; 18:569-72
5. Omoke, NI. & Madubueze, CC. Machete injuries as seen in a Nigerian teaching hospital. *Injury* 2010; 41, 120–124.
6. Obimakinde OS, Okoje VN, Fasola AO. Pattern of assault induced oral and maxillofacial injuries in Ado-Ekiti, Nigeria. *Nigerian J Surg* 2012; 18(2): 88-90.
7. Donnally, C.J., Hannay, W., Rapp, D.A. *et al.* Machete injuries to the upper extremity. *Arch Orthop Trauma Surg* 137, 1615–1621 (2017). <https://doi.org/10.1007/s00402-017-2783-y>
8. Crandon IW, Harding HE, Cawich SO, Webster D (2011) Complicated head trauma from machete wounds: the experience from a tertiary referral hospital in Jamaica. *Int J Inj Contr Saf Promot* 18(4):293–297. doi:[10.1080/17457300.2011.569890](https://doi.org/10.1080/17457300.2011.569890)
9. Holder MK. Why are more people right-handed? *Scientific American Inc.*;1997. Available from: <http://www.Sciam.com>. [Last retrieved on 2008Apr 14].
10. Akinbami BO. Evaluation of the mechanism and principles of management of temporomandibular joint dislocation. Systematic review of literature and a proposed new classification of temporo- mandibular joint dislocation. *Head Face Med* 2011; 7:10.
11. Ugboko VI, Oginni FO, Ajike SO, et al. A survey of temporomandibular joint dislocation: aetiology, demographics, risk factors and management in 96 Nigerian cases. *Int J Oral Maxillofac Surg* 2005; 34:499–502.
12. Abbaszadeh-Kasbi A, Kouhi A, Ashtiani MTK, Anari MR, Yazdi AK, Emami H. Conservative versus Surgical Therapy in Managing Patients with Facial Nerve Palsy Due to the Temporal Bone Fracture. *Cranio-maxillofac Trauma Reconstr.* 2019 Mar; 12(1): 20-26. doi: 10.1055/s-0038-1625966.

Copyright (c) 2021 The copyright to the submitted manuscript is held by the Author, who grants the Clinical Medicine And Health Research Journal a nonexclusive license to use, reproduce, and distribute the work, including for commercial purposes.



This work is licensed under a [Creative Commons Attribution 4.0 International License](https://creativecommons.org/licenses/by/4.0/)