

Research Article

Outcome of Arthroscopic Synovectomy for Diffuse Pigmented Villonodular Synovitis of the Knee in Sudanese Patients

Gaafar Siddig Awad Alseed¹, Mohamed Hamid Awadelseid², Omer Yaseen Almubarak³

¹Departement of Orthopedic Hag Elsafi Teaching Hospital-Khartoum, Sudan

²Departement of Pediatric Orthopedic Excellence Trauma Centre Khartoum, Sudan

³Departement of Orthopedic Hag Elsafi Teaching Hospital-Khartoum, Sudan

Received: 10 June, 2022

Accepted: 15 July, 2022

Published: 19 July 2022

Abstract:

Background: Diffuse pigmented villonodular synovitis (DPVNS) of the knee is a difficult tumor to eradicate, the gold standard treatment has traditionally been surgical excision with total synovectomy of the affected joint, either with an open or arthroscopic approach. In this study, we are focusing on arthroscopic surgical synovectomy.

Objectives: Aimed to study the outcome of arthroscopic synovectomy for diffuse pigmented villonodular synovitis of the knee in Haj Alsafi Teaching Hospital.

Methodology: Observational retrospective hospital-based study, performed in the Orthopedic Department, 12 patients (8 males and 4 females) with the diffuse form of PVNS of the knee were enrolled in the study after qualification. The clinical diagnosis was confirmed by magnetic resonance imaging and post-surgical histo-pathological examination. All patients underwent complete synovectomy through standard anterior, medial and lateral, then medial, lateral suprapatellar and posteromedial portals. Each patient was evaluated before and after treatment and followed up for a minimum of 18 months (range: 18 – 54 months) using the Lysholm score and International Knee Documentation Committee (IKDC) score.

Results: The average age group of patients was (9–63years) with male predominance (66.7 %). Left knee more frequently affected(58.3%). None of the study participants had previous surgical history 100%. Both Lysholm and IKDC scores were significantly improved in all study participants. Regarding paired sample statistics, the mean for the score preoperatively and postoperatively was improved from 54.9 to77.9.Recurrence reported in one participant (8.3%). There was a statistical association between pre and post-operative LYSHOLM and IKDC scores and recurrence, hence p-value =0.000.

Conclusion: Arthroscopic synovectomy is an appropriate treatment for knee DPVNS with a good clinical and functional outcome and with a low recurrence rate.

Key words: knee - pigmented villonodular synovitis – Arthroscopic synovectomy.

Introduction

The human knee is the largest joint in the musculoskeletal system, which supports the body weight and facilitates locomotion. The knee consists of two distinct articulations, the tibiofemoral and the patellofemoral joints[1]. The tibiofemoral joint is one of the most complex articulations of the human body and its main tissues are the femur, tibia, fibula, articular cartilages, menisci, and ligaments. The tibiofemoral joint enables the relative motion of the femur and tibia, which is facilitated through mechanical contacts between the cartilages and menisci [2].

Joint capsule: The capsule surrounds the knee joint. It has a tough, fibrous outer membrane and an inner synovial membrane, which produces joint fluid (synovial fluid). This fluid lubricates the joint and nourishes the articular cartilage that coats the ends of the bones in the joint. Numerous bursae or small fluid sacs are like folds in the capsule around the knee

joint which provide extra flexibility and stretch to the capsule. Articular Cartilage is a thin, elastic connective tissue protects the bone by absorbing shock. Cartilage also ensures that joint surfaces slide easily over each other for smooth knee movement. Meniscal cartilage is fibrous with a good tensile strength, separating the bones of the knee and acting as a shock absorber. The meniscus can often be torn in forceful, twisting injuries. There are two c-shaped menisci in the knee – the medial meniscus and the lateral meniscus.

Ligaments: There are four main ligaments which strap the bones of the knee joint together. They are the anterior cruciate ligament (ACL), the posterior cruciate ligament (PCL), the medial collateral ligament (MCL) and the lateral collateral ligament (LCL). The ligaments surrounding the knee joint offer stability by limiting movements and, together with several menisci and bursae, protect the articular capsule. The knee joint consists of three “compartments” or sections: medial compartment (inner half of the knee), lateral compartment

(outer half of the knee) and patellofemoral compartment (behind the knee). Pigmented villonodular synovitis (PVNS) is a rare proliferative process that affects the synovial joints, tendon sheaths, and bursae. In 1852, Chassaignac [3] reported the first case of a lesion in the flexor tendon sheath of the second and third fingers; this was subsequently reported in other joints. In 1941, Jaffe et al [4] coined the term "pigmented villonodular synovitis"; subsequently, Granowitz et al [5] expanded the terminology, distinguishing the localized (LPVNS) and diffuse (DPVNS) forms from other synovial lesions. Recently, the World Health Organization (WHO) has defined PVNS and giant cell tumor to be equivalent terms [6].

The estimated incidence of PVNS ranges around 1.8 per million. It is usually monoarticular, affecting large joints. The knee is the most affected site (28%–70%), but cases in the hip, ankle, shoulder, and elbow are often observed [7].

The disease presents in two forms, localized or diffuse, and both types have similar appearance: a synovial membrane characterized by inflammation and presence of hemosiderin deposits [8]. Microscopically, it is characterized by the presence of lipid-laden macrophages, multinucleated giant cells, hemosiderin deposits, and proliferation of fibroblasts and stromal cells. LPVNS is characterized by discrete or pedunculated nodular lesions. In turn, DPVNS is the most common presentation, involving intra-articular tissues; it may have extra-articular extension, behaving as a chronic process [9].

In the last 100 years, little progress has been made regarding treatment. The goal of PVNS treatment is to remove all synovial tissue in order to relieve pain, decrease the risk of joint destruction, and prevent local recurrence. Several treatment options have been proposed for this disease in cases of genicular involvement, ranging from observation and radical local surgery to total knee arthroplasty [10]. Pigmented villonodular synovitis (PVNS) is a benign, locally aggressive, neoplastic process of the joints, particularly the synovial membrane or tendon sheaths. PVNS can affect various joints, with 1.8 new cases per million persons per year [11]. Studies from the US and UK report a greater prevalence among males [12], whereas retrospective studies in China report a female predominance [13]. As do series from France, Portugal, and Italy. PVNS usually occurs in the age of 30s or 40s to 50s [14].

PVNS most commonly affects the large joints, such as the knees, hips, and ankles. There is a predilection for the knee, with rates as high as 74%. PVNS often presents with pain and swelling of the joint [15]. Proper diagnosis is often delayed from 16 months to even 5 years owing to the nonspecific symptoms [16].

General objectives:

To study the outcome of arthroscopic synovectomy for diffuse pigmented villonodular synovitis of the knee in Sudanese patients.

Specific objectives:

To determine the functional and clinical outcome of the knee post arthroscopic synovectomy.

Methodology

This is Observational retrospective hospital based study. All patients underwent arthroscopic synovectomy for diffuse pigmented villonodular synovitis of the knee.

Inclusion criteria:

- Patients of DPVNS of the knee treated with arthroscopic synovectomy.
- Follow up more than 18 months.
- Patients of all ages
- Both sexes

Exclusion criteria:

DPVNS other than the knee

Patients treated with other surgical and non-surgical modalities.

Total coverage for all patients due to rare cases. The datasheets from hospital statistical department available just for 12 patients. Data collection carried out by the principal investigator, from patient's data sheets composed of:

- Lysholm knee scoring scale.
- International Knee Documentation Committee Score (IKDCS score).

The collected data was analyzed by using Statistical Package for the Social Studies Program SPSS, V. 24.0. IBM then presented as figures, frequency and percentage tables. .

An ethical approval obtained from Sudan medical specialization board (SMSB).

Surgical Technique:

Arthroscopy was performed in supine position under spinal anaesthesia with a tourniquet applied high on the thigh. The knee was flexed 90 degrees by draping the leg over the edge of the operative table. Standard lateral and medial portals were made. The 30 degree arthroscope was used. The procedure done with complete synovectomy of the anterior compartment, posterior compartment and suprapatellar pouch. Anterior compartment: was started with medial part synovectomy, with applying valgus stress, medial submeniscal synovectomy was done. Then, the notch area and in between ACL and PCL. Then, the lateral part and also, lateral sub meniscal area with applying the figure of four positions. All were meticulously shaved and cleaned. The posterior compartment: (posteromedial, posterolateral and middle third septum) was approached using posteromedial portal. The suprapatellar pouch: was completely shaved through medial and lateral suprapatellar portals, including the lateral gutter, the popliteal hiatus area, and the medial gutter. The synovium was shaved till post capsule i.e. shaving the reddish synovium till reaching white area, and it is our suggestion that less damage post capsule causes less chance of extravasation and probably compartment syndrome. Portals were not sutured except the entrance of the drain. Arthroscopic electro-ablation was done

just when an oozing vessel seen. In this study, synovectomy was performed using different shavers (5.5mm, 4.5mm, 3.5mm shaver blades diameter, straight and curved) to ensure adequacy of debridement.

Results

Baseline characteristics of patients: This study includes 12 patients 8 (66.7%) males and 4 females, their mean age was 29 years (range: 9 – 63 years), 2 (16.7%) cases were children (9 and 11 years).

The Left limb was affected in 7 cases (58.3%) and the right one 5. Patients were followed up for a minimum of 18 months (range: 18 – 54 months). The clinical diagnosis was confirmed by magnetic resonance imaging and post-surgical pathologic examination. In these patients, the most frequent preoperative symptoms were joint effusion, true recurring hemarthrosis, and mild pain. In some cases, the presence of articular locking or pseudo locking was noticed.

Clinical and functional outcomes: All cases underwent arthroscopic synovectomy and evaluated before treatment and at the final follow up visit using the Lysholm score and International Knee Documentation Committee score (IKDCs). No patient reports a history of previous knee surgery and all of them have an excellent knee function before the injury (IKDC score prior injury was 10 for 10 cases and 9 for 2 cases, (table1). There were no complications during or after the

arthroscopic procedure. One patient (8.3%) displayed evidence of local recurrence (figure 1) after 30 months of synovectomy which was confirmed by MRI, and he developed the disease in the other knee. The limitation of joint motion, Lysholm knee joint function score and IKDC score were improved significantly postoperatively. Regarding paired sample statistics, the mean for the score preoperatively and postoperatively was improved from 54.9 to 77.9

There was a statistical association between preoperative and postoperative LYSHOLM and IKDC scores and recurrence, hence p-value =0.000.

8.3% of the study participants had history of recurrence, as shown in figure (1) below:

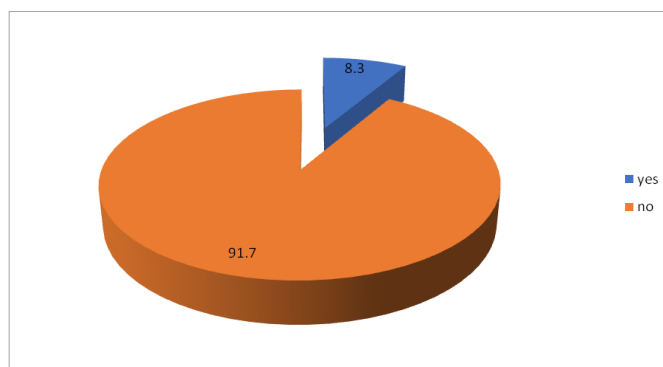


Figure (1) Recurrence history among study participants, n=12

Table (1): General data of the patients

No	Age years	Gender	Follow-up months	R/L knee	IKDC prior injury	LYSHOLM score pre	LYSHOLM score post	IKDC s score %	Previous surgery	Recur
1	11	Male	36	Right	10	51	74	74.7	No	No
2	63	Male	18	Left	9	51	80	79.3	No	No
3	17	Male	30	Left	10	38	56	56.3	No	Yes
4	30	Male	28	Right	10	60	80	81.6	No	No
5	26	Male	43	Left	10	57	70	71.2	No	No
6	42	Female	53	Left	10	62	90	90.8	No	No
7	28	Female	34	Left	10	49	78	78.7	No	No
8	21	Male	48	Right	10	72	87	87.3	No	No
9	19	Male	48	Right	10	53	69	70.1	No	No
10	54	Female	54	Left	9	52	75	74.7	No	No
11	9	Female	39	Right	10	47	90	91.9	No	No
12	30	Male	36	Left	10	69	86	86.2	No	No

LYSHOLM: Maximum possible points =100

IKDC s: Maximum possible points =87

IKDC Score:= (sum of item /maximum score) x 100 = %

IKDC prior injury: Function of the knee before the illness, scores of 0 to 10 with 10 being normal, excellent function and 0 being the inability to perform any of the usual daily activities which may include sport.

Discussion

PVNS is a rare disease of which the diagnosis is often delayed. This may result in the extension of the disease and the involvement of the adjacent soft and bone tissues. The disease may become gradually more aggressive and recurrence occurs frequently. PVNS must be considered in patients who present with joint effusion and develop contracture, and their

examinations should be performed accordingly. If possible, the probability of recurrence should be minimized through aggressive radical synovectomy. There is no definitive treatment method. The mainstay of treatment has been surgical or arthroscopic synovectomy. Arthroscopic synovectomy has reduced morbidity and is well tolerated by patients. Open

surgical synovectomy causes stiffness and pain and has a long recovery time, mainly after procedures involving the knee joint. However, the relapse rates of both approaches are reported to be relatively high, ranging between 8% and 46%.

The common presenting patients complains in this study were tolerable knee pain and swelling with or without one or more of the followings: limp, instability, locking or catching sensation. Twelve patients who had a diagnosis of DPVNS of the knee were followed for an average of 3years (range, 1.5 to 4.5 years) after complete arthroscopic synovectomy. In the present study majority, 66.7% of the participants were males, (with male to female ratio2:1), Keyhani S et al stated that male to female ratio was 2.5:1 [18]. Which is supports our findings, in contrast, HoudekMT, et al study which reported 58% were females and 42% were males [18]. Mollon B et al study also reported the predominant of females (80%) [17], this variation may due to the small sample size included in the study.

16.7% of our study participants were in their 30 years old and the same percentage were children (9,11 years), with age range from 9-63 years old (average age 29 years) similar findings obtained by Gouin F et al, reported average age of 33 years [19], and De Visser et al revealed mean age was 32 (range 12–72) years [20].

Regarding the LYSHOLM score and IKDCS: all patients scoring better after the operation, the mean LYSHOLM score was improved from 54.9 preoperatively to77.9 postoperatively which is significant. Keyhani S et al revealed both Lysholm score and IKDC scores were significantly improved in all study participants [18].

In this study, recurrence was reported in one patient (8.3%) of the study participants, while a higher recurrence percentage reported by Mollon B et al study was 13 % of patients experienced symptomatic disease recurrence [17]. While Keyhani S et al reported no cases of clinical recurrence, infection, joint stiffness, or neurovascular lesions were observed [18]. In the study of Kotwal et al., it was noted that the factors contributing to the risk of recurrence were incomplete excision, mitotic activity and bone involvement [21].

The final common pathway of DPVNS of the knee leads to total joint destruction, which eventually leads to the need for joint replacement. This should be avoided if possible, especially in these young and healthy patients.

Conclusion

The results of this study proved that: Arthroscopic synovectomy is ideal for treating DPVNS with good clinical and functional outcome and low recurrence rate.It has the advantages of minimal complications, minimal invasion and fast post-operative recovery.All abnormal synovial tissue must be eradicated, thereby removing the risk of further jointdestruction and recurrence. Although DPVNS is a rare condition in pediatric patients,it should be considered in differential diagnosis of any arthritis in children.

Recommendations

The study recommends that: To consider using arthroscopic

synovectomy as good option for treatment of diffuse pigmented villonodular synovitis of the knee. To emphasize that early diagnosis and well done arthroscopic synovectomy gives good clinical outcome with low recurrence rate. Further researches with large samples comparing arthroscopic synovectomy with other modalities of treatment required.

- **Compliance with ethical standards**
- **Acknowledgments:** Department of orthopedic Hagelsfi Hospital who contributed by any mean to the success of this study.
- **Conflict of interest:** None to declare
- Statement of informed consent

Approval of this study was obtained from our institutional review board

References:

1. Shrive NG, O'Connor JJ, Goodfellow JW. Load-bearing in the knee joint. *Clinical Orthopaedics and Related Research*. 1978;131:279–287.
2. Chassaignac CM. Cancer de la gaine des tendons. *Gaz Hop Cive Milit*. 1852;47:185-6.
3. Jaffe HL. Pigmented villonodular synovitis, bursitis, and tenosynovitis. *Arch Pathol*. 1941;31:731-65.
4. GRANOWITZ SP, MANKIN HJ. Localized pigmented villonodular synovitis of the knee: report of five cases. *JBJS*. 1967 Jan 1;49(1):122-8.
5. MYERS BW, MASI AT, FEIGENBAUM SL. Pigmented villonodular synovitis and tenosynovitis: a clinical epidemiologic study of 166 cases and literature review. *Medicine*. 1980 May 1;59(3):223-38
6. Rodriguez- Merchan EC. Openversus arthroscopic synovectomy for pigmented villonodular synovitis of the knee. *Journal of Orthopaedic Surgery*.2014 Dec;22(3):406-8.
7. Yang B, Liu D, Lin J, Jin JI, Weng XS, Qian WW, Qian J. Surgical treatment of diffuse pigmented villonodular synovitis of the knee. *Zhongguo yi xue ke xue yuan xue bao. Acta Academiae Medicinae Sinicae*. 2015 Apr;37(2):234-9.Oehler ST, Fassbender HG, Neureiter DA, Meyer-Scholten CA, Kirchner TH, Aigner TH. Cell populations involved in pigmented villonodular synovitis of the knee. *The Journal of rheumatology*. 2000 Feb;27(2):463-70
8. Bemporad JA, Chaloupka JC, Putman CM, Roth TC, Tarro J, Mitra S, et al. Pigmented villonodular synovitis of the temporomandibular joint: diagnostic imaging and endovascular therapeutic embolization of a rare head and neck tumor. *AJNR Am J Neuroradiol*. 1999;20:159-62.
9. Korim MT, Clarke DR, Allen PE, Richards CJ, Ashford RU. Clinical and oncological outcomes after surgical excision of pigmented villonodular synovitis at the foot and ankle. *Foot Ankle Surg*. 2014;20:130-4.
10. Xie GP, Jiang N, Liang CX, Zeng JC, Chen ZY, Xu Q, et al. Pigmented villonodular synovitis: a retrospective multicenter study of 237 cases. *PLoS One*. 2015;10:e0121451.

11. Ma X, Shi G, Xia C, Liu H, He J, Jin W. Pigmented villonodular synovitis: a retrospective study of seventy five cases (eighty one joints). *Int Orthop*. 2013;37:1165-70.
12. Palmerini E, Staals EL, Maki RG, Pengo S, Cioff A, Gambarotti M, et al. Tenosynovial giant cell tumour/pigmented villonodular synovitis: outcome of 294 patients before the era of kinase inhibitors. *Eur J Cancer*. 2015;51:210-7.
13. Ottaviani S, Ayril X, Dougados M, Gossec L. Pigmented villonodular synovitis: a retrospective single-center study of 122 cases and review of the literature. *Semin Arthritis Rheum*. 2011.
14. De Ponti A, Sansone V, Malchere M. Result of arthroscopic treatment of pigmented villonodular synovitis of the knee. *Arthroscopy*. 2003;19:602-7.
15. Loriaut P, Djian P, Boyer T, Bonvarlet JP, Delin C, Makridis KG. Arthroscopic treatment of localized pigmented villonodular synovitis of the knee. *Knee Surg Sports Traumatol Arthrosc*. 2012;20:1550-3.
16. Mollon B, Griffin AM, Ferguson PC, Wunder JS, Theodoropoulos J. Combined arthroscopic and open synovectomy for diffuse pigmented villonodular synovitis of the knee. *Knee Surgery, Sports Traumatology, Arthroscopy*. 2016 Jan 1;24(1):260-6.
17. De Carvalho Jr LH, Soares LF, Gonçalves MB, Temponi EF, de Melo Silva Jr O. Long-term success in the treatment of diffuse pigmented villonodular synovitis of the knee with subtotal synovectomy and radiotherapy. *Arthroscopy: The Journal of Arthroscopic & Related Surgery*. 2012 Sep 1;28(9):1271-4.
18. Singh R., Grewal D.S., Chakravarti R.N. Experimental production of pigmented villonodular synovitis in the knee and ankle joints of rhesus monkeys. *J Pathol*. 1969;98(2):137-142.
19. Hirohata K. Light microscopic and electron microscopic studies of individual cells in pigmented villonodular synovitis and bursitis (Jaffe) Kobe *J Med Sci*. 1968;14(4):251-279.
20. Houdek MT, Scorianz M, Wyles CC, Trousdale RT, Sim FH, Taunton MJ. Long-term outcome of knee arthroplasty in the setting of pigmented villonodular synovitis. *The Knee*. 2017 Aug 1;24(4):851-5
21. Flandry F., Hughston J.C., McCann S.B., Kurtz D.M. Diagnostic features of diffuse pigmented villonodular synovitis of the knee. *Clin Orthop Relat Res*. 1994;(298):212-22.

Copyright (c) 2021 The copyright to the submitted manuscript is held by the Author, who grants the Clinical Medicine And Health Research Journal a nonexclusive license to use, reproduce, and distribute the work, including for commercial purposes.



This work is licensed under a [Creative Commons Attribution 4.0 International License](https://creativecommons.org/licenses/by/4.0/)