

## Case Report

# Laparoscopic Management of Cholecystoduodenal Fistula Associated with Sclerotic Gallbladder: Case Report

Jonathan E. Quimis<sup>1</sup>, Mayling B. Chusan<sup>1</sup>, Juan R. Molina<sup>1</sup>, Erick H. Zambrano<sup>1,2</sup>, Jose F. Calderón<sup>2</sup>, Gema G. Plaza<sup>2</sup>, Luis A. Muñoz<sup>1,2</sup>

<sup>1</sup>IESS Los Ceibos, General Surgery Department, Guayaquil 090615, Ecuador.

<sup>2</sup>SOLCA Oncologic Surgery, Guayaquil 090505, Ecuador.

**Received: 17 December, 2024 : Accepted: 20 January, 2025 : Published: 25 January 2025**

### Abstract:

Cholecystoduodenal fistula (CDF) is a rare and complex complication of chronic cholecystitis and gallstone disease, characterized by an abnormal communication between the gallbladder and duodenum. This report presents the case of a 31-year-old male who presented with right upper quadrant pain, nausea, and jaundice. Imaging studies confirmed a scleroatrophic gallbladder and a CFD. The patient underwent laparoscopic cholecystectomy with partial gallbladder excision, and the fistula was successfully repaired with laparoscopic techniques, including clip application and intracorporeal suturing to invaginate the defect. This case underscores the importance of advanced laparoscopic skills and multidisciplinary approaches in managing complex biliary pathologies.

**Key words:** Cholecystoduodenal fistula, sclerotic gallbladder, laparoscopic surgery, biliary diseases, advanced surgical techniques.

### Introduction

Cholecystoduodenal fistula (CDF) is a rare complication of chronic gallstone disease, occurring in less than 0.5% of patients [1, 2]. It is often associated with chronic inflammation and erosion of the gallbladder into the duodenum, facilitated by longstanding gallstones. Surgical management of CDF presents challenges due to the presence of dense adhesions, distortion of anatomy, and the risk of duodenal injury.

Advancements in laparoscopic techniques have enabled minimally invasive approaches for CDF management, offering shorter hospital stays and lower morbidity [3, 4]. However, successful laparoscopic repair requires precise dissection, meticulous hemostasis, and effective defect closure. This report describes the laparoscopic management of CDF in a patient with a scleroatrophic gallbladder and provides a detailed surgical account supported by a review of the literature.

### Materials and Methods

#### Patient Data

This case study was conducted at the IESS CEIBOS, Guayaquil, Ecuador. Data were retrospectively collected, including clinical history, imaging, intraoperative findings, and follow-up outcomes.

#### Preoperative Assessment

A 31-year-old male presented with right upper quadrant pain, nausea, and mild jaundice. Laboratory findings showed elevated bilirubin (10.7 mg/dL), lipase (1432.29 U/L), and amylase (362.56 U/L). Imaging revealed:

1. **Ultrasound:** A contracted gallbladder with thickened walls and multiple calculi.
2. **CT scan:** Scleroatrophic gallbladder adherent to the duodenum with a visible fistulous connection (Figures 1, 2, and 3).

The patient was stabilized with intravenous fluids, analgesics, and antibiotics. A laparoscopic approach was chosen for definitive management.

### Results and Discussion

#### Intraoperative Findings

Laparoscopy revealed a scleroatrophic gallbladder with dense adhesions to the duodenum and colon. The fistula was located on the anterior wall of the duodenum, measuring approximately 1 cm in diameter. Intraoperative images captured the fistula before and after dissection (Figures 4 and 5).

#### Surgical Technique

- **Adhesiolysis:** Adhesions were carefully dissected using monopolar energy and blunt dissection, fully mobilizing the gallbladder and exposing the fistula.
- **Fistula Clip Application:** The fistulous tract was clipped proximally at the gallbladder and distally near the duodenum using titanium clips to ensure secure occlusion and minimize bile spillage.
- **Defect Closure with Intracorporeal Suturing:** The duodenal defect was closed in two layers. The first layer involved interrupted sutures for defect approximation, followed by a second continuous layer to invaginate the

repair and reinforce the closure. Suturing was performed with 3-0 absorbable monofilament using a needle driver and assistant graspers.

- **Partial Cholecystectomy:** The gallbladder was removed partially due to severe fibrosis, leaving a secure stump closed with clips and sutures.

### Postoperative Course

The patient was discharged on postoperative day three without complications. Follow-up imaging confirmed no recurrence of the fistula or residual biliary disease. Histopathology showed chronic inflammation without malignancy.

The laparoscopic management of CDF in this case illustrates the role of advanced surgical techniques in addressing complex biliary conditions. The use of intracorporeal suturing to invaginate the defect, combined with clip placement, ensured a watertight closure of the fistula, minimizing the risk of postoperative bile leakage or duodenal perforation [5, 6].

Preoperative imaging, particularly contrast-enhanced CT, was instrumental in identifying the fistula and guiding surgical planning [7, 8]. While open surgery remains the traditional standard for managing CDF, laparoscopic approaches have demonstrated comparable safety and efficacy, with the added benefits of faster recovery and reduced postoperative pain [9, 10]

### Placement of Images

- **Figures 1, 2, and 3:** CT images showing the contracted gallbladder and fistula.

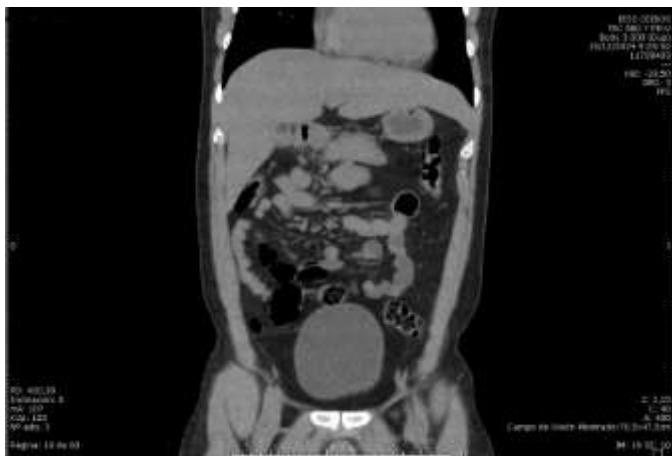

Figure 1: Coronal view of the gallbladder adhered to the duodenum.

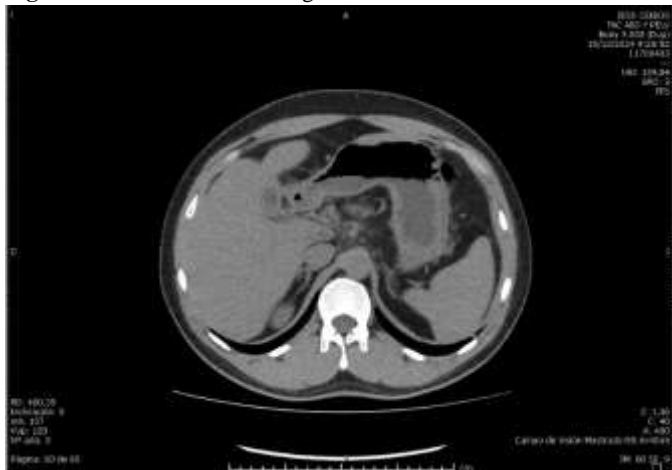


Figure 2: Axial view demonstrating the fistulous tract.

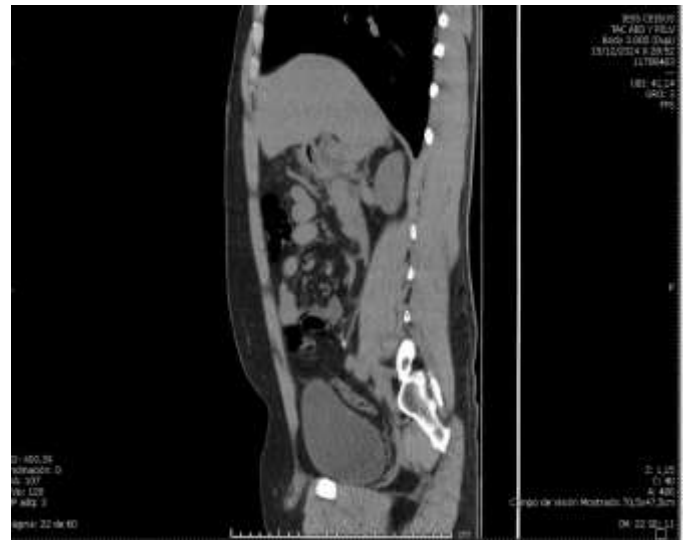


Figure 3: Sagittal view highlighting the anatomical relationship of the fistula.

- **Figures 4 and 5:** Intraoperative images of the fistula.

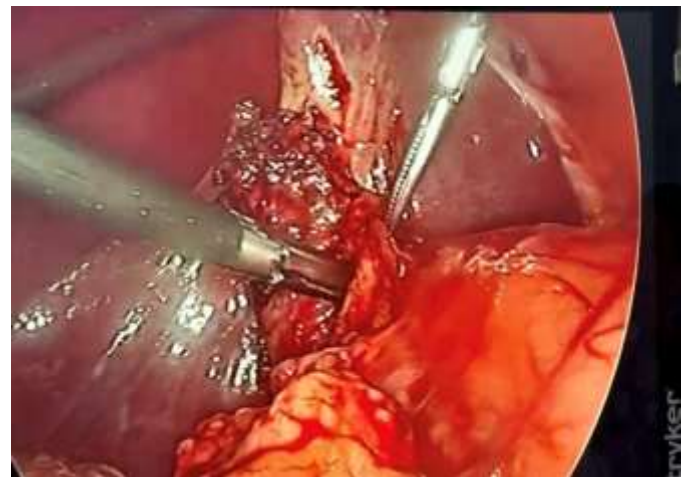

Figure 4: Fistula before dissection, showing its anatomical location.

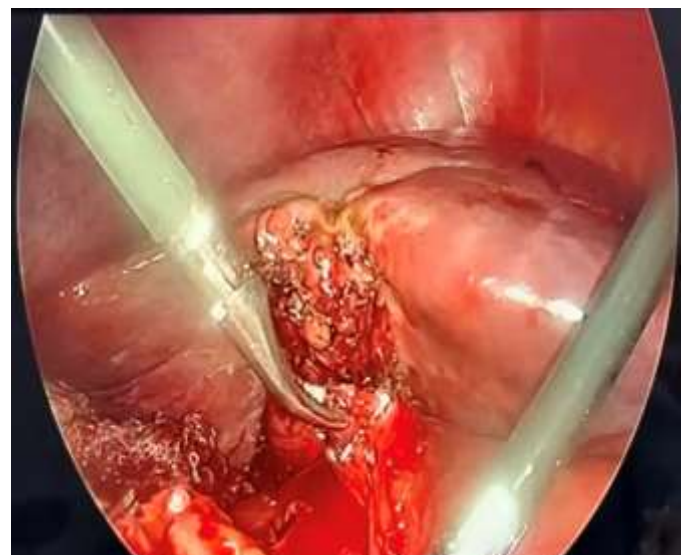


Figure 5: Post-dissection image showing the clipped fistula.

### Conclusions

Laparoscopic repair of cholecystoduodenal fistula, involving meticulous dissection, clip application, and intracorporeal suturing, is a viable and effective approach for managing complex biliary conditions. The case highlights the importance of preoperative imaging, intraoperative precision, and advanced

laparoscopic skills in achieving optimal outcomes.

#### **Ethics approval and consent to participate**

Not applicable

#### **List of abbreviations**

CDF: Cholecystoduodenal fistula.

#### **Data Availability**

Data supporting the findings are available upon reasonable request.

#### **Conflicts of Interest**

The authors declare that there is no conflict of interest regarding the publication of this paper.

#### **Funding Statement**

No funding was received for this study

#### **Authors' contributions**

LAM reviewed and approved the final manuscript. JEQ performed the surgery, analyzed the data, and drafted the manuscript. MBC assisted as the first surgical assistant during the procedure. JRM assisted as the second surgical assistant. EHZ conducted the literature review and provided critical revisions. JFC contributed to manuscript drafting and editing. GGP assisted with manuscript writing and editing.

#### **Acknowledgments**

The author thanks the surgical team at IESS CEIBOS.

#### **References**

1. A. Bedirli, O. Sakrak, E. M. Sozuer et al., "Surgical management of cholecystoduodenal fistulas: a clinical study of 12 patients," *Hepatogastroenterology*, vol. 48, no. 39, pp. 1208–1211, 2001.
2. R. Costi, B. Randone, V. Violi et al., "Cholecystocolonic fistula: facts and myths," *J Hepatobiliary Pancreat Surg*, vol. 16, no. 1, pp. 8–18, 2009.
3. F. Glenn, C. Reed, and W. R. Grafe, "Biliary enteric

fistula," *Surg Gynecol Obstet*, vol. 153, no. 4, pp. 527–531, 1981.

4. P. K. Chowbey, V. Khullar, A. Sharma et al., "Laparoscopic management of cholecystoenteric fistulas," *J Laparoendosc Adv Surg Tech A*, vol. 16, no. 5, pp. 467–472, 2006.
5. J. H. Kim, H. Y. Park, S. J. Kim et al., "Chronic cholecystitis and its complications: insights into imaging and management," *J Hepatobiliary Surg*, 2020.
6. S. M. Strasberg, "Acute calculous cholecystitis," *N Engl J Med*, vol. 358, no. 26, pp. 2804–2811, 2008.
7. J. L. Cameron and A. M. Cameron, *Current Surgical Therapy*, Elsevier, 13th ed., 2019.
8. V. Agrawal, S. Mohanty, and R. K. Misra, "Cholecystoduodenal fistula: a clinical challenge," *Int J Surg Case Rep*, vol. 10, pp. 123–126, 2015.
9. L. M. Brunt, D. J. Deziel, D. A. Telem et al., "Safe cholecystectomy: incorporating the critical view of safety and preventing bile duct injury," *J Am Coll Surg*, vol. 231, no. 2, pp. 264–276, 2020.
10. J. W. Park, K. H. Kim, and S. H. Park, "Surgical approaches to cholecystoduodenal fistula: laparoscopic experience," *Ann Surg Innov Res*, vol. 16, no. 4, pp. 202–210, 2022.

Copyright (c) 2025 The copyright to the submitted manuscript is held by the Author, who grants the Clinical Medicine and Health Research Journal a nonexclusive license to use, reproduce, and distribute the work, including for commercial purposes.



This work is licensed under a [Creative Commons Attribution 4.0 International License](https://creativecommons.org/licenses/by/4.0/)