

Research Article

Chronic Thromboembolic Pulmonary Hypertension Becoming of a Patient Followed Since the Age Of 10

M. ABDELBAKI¹, Z. BENNOUI²

¹Cardiology department EHS Maouche M. Amokrane

²Cardiology Department, Tipaza Hospital

Received: 08 April, 2023

Accepted: 10 May, 2024

Published: 15 May 2024

Abstract:

Chronic thromboembolic pulmonary hypertension occurs after one or more episodes of pulmonary embolism. A rigorous diagnostic approach makes it possible to identify this condition, to evaluate its functional and hemodynamic impact and to determine the degree of extension of the vascular damage. Surgical pulmonary endarterectomy in specialized centers remains the treatment of choice in certain cases. Other therapeutic modalities include transplantation, pulmonary angioplasty, and pharmacological treatments with pulmonary vasodilators. We report the case of OA aged 25, followed since the age of 10 for post-embolic PAH. She was hospitalized at this age in pediatrics for the first episode of pulmonary embolism. The initial etiological assessment was without abnormalities. One year after pulmonary embolism, pulmonary pressures were still elevated despite effective anticoagulation. The patient was started on sildenafil at the age of 11. The evolution was stable. At the age of 16, she was referred to us for care. Her cardiovascular assessment revealed suprasystemic PAH; the patient was then put on a combination of sintrom, sildenafil and bosentan. The thrombophilia assessment is without abnormalities. Currently, she is 25 years old, she is in NYHA functional class II on dual therapy, she has presented several right heart decompensations following non-compliance with treatment and dietary deviation. We discussed a surgical endarterectomy at her home but unfortunately the damage is distal and old. Through this case, we will review this entity of PAH by discussing the different modes of expression and the medical, surgical and interventional therapeutic management (pulmonary angioplasty with a balloon).

Keywords: pulmonary embolism, familial SAPLE, chronic post-embolic PAH, iterative right heart decompensation, drug treatment, endarterectomy, interventional treatment.

Introduction

Chronic post-embolic pulmonary hypertension (CPE-PH) is a rare and serious, potentially curable disease. It is underdiagnosed due to the absence of specific clinical signs. It occurs in a predisposed area such as certain thrombophilias (anti-cardiolipin antibodies, high factor VIII levels), splenectomy, ventriculo-atrial diversions, inflammatory bowel diseases, osteomyelitis, myeloproliferative syndromes (1, 2), pressure elevated pulmonary artery disease during the acute episode of pulmonary embolism, thyroid hormone replacement therapy and history of cancer. The persistence and organization of thrombi in fibrous material at the level of the pulmonary arteries leads to pulmonary arterial obstruction inducing an increase in pulmonary pressure and resistance. Shearing phenomena in non-occluded territories have been described, leading to a true small vessel arteriopathy identical to that of idiopathic PAH (1). These disturbances are the cause of right heart failure. The diagnosis is suspected in the presence of exertional dyspnea, chest pain or right heart failure. Sometimes a history of pulmonary embolism or thromboembolic disease can guide the diagnosis. In 55% of cases, the diagnosis of PH-PEC is made following an etiological assessment of PAH, in 10% of cases, it is a persistent PH after an episode of pulmonary

embolism and in 35% of case, it is a picture of acute pulmonary embolism revealing PH (3,4, 5). In a prospective follow-up study of patients who had a pulmonary embolism, a prevalence of 3.8% of CPE-PH was described (6). According to an international registry, the median age of patients with this pathology is 63 years. Note that even patients under 20 years old can be affected (4, 5). In the absence of treatment, life expectancy does not exceed 5 years in 10% of cases (7). Cardiac Doppler ultrasound makes it possible to evaluate pulmonary pressures and resistance. The diagnosis of PH-PEC is confirmed by ventilation/perfusion lung scintigraphy. Multi-array thoracic helical CT may show obstruction or a reduction in the diameter of the arterial lumen relative to the external diameter (2). CPE -PH is a form of PAH that can be successfully treated with surgery (8). Treatment is based on recommendations 2009(1) in long-term anticoagulation with pulmonary endarterectomy. Patient selection must be based on the location and extension of the thrombus, the degree of PH and the presence of comorbidities. Specific drug treatments are prescribed to patients who are not candidates for surgery or in whom PH persists after surgery (1,9-13)

We report the case of OA aged 25, followed since the age of 10 for post-embolic PAH. She was hospitalized at this age in pediatrics for the first episode of pulmonary embolism. The

initial etiological assessment was without abnormalities. One year after pulmonary embolism, pulmonary pressures were still elevated despite effective anticoagulation. The patient was started on sildenafil at the age of 11. The evolution was stable. At the age of 16, she was referred to us for care. In his family history, we learn that two members of his siblings as well as the mother were explored for venous thrombosis of the lower limb and that the results were in favor of SAPLE. His family members refuse any medical follow-up. Her cardiovascular assessment revealed chronic post-embolic suprasystemic PAH and the patient was then put on a combination of sintrom, sildenafil and bosentan. The thrombophilia assessment is without abnormalities. Currently, and at 25 years old, the patient is in NYHA functional class II on dual therapy, she has presented several right heart decompensations following non-compliance with treatment and dietary deviation. We discussed a surgical endarterectomy at her home but unfortunately the damage is distal and old.

Discussion

Chronic post-embolic pulmonary hypertension (CPE-PH) is a form of pulmonary hypertension occurring after one or more pulmonary embolisms. CPE-PH is characterized by pulmonary arterial pressure greater than 20 millimeters of mercury (mm Hg), high pulmonary vascular resistance (1) with the presence of at least one perfusion defect on lung scintigraphy, and angiography pulmonary and/or a chest CT angiogram showing abnormalities characteristic of the disease (Figure 1). Several mechanisms lead to impaired clot elimination (impaired physiological fibrinolysis, platelet activation, impaired angiogenesis). The clinical manifestations of CPE-PH are not specific; it is mainly exertional dyspnea, which progressively worsens. Other symptoms may occur during the course of the disease: asthenia, faintness or syncope, chest pain, right heart failure in the final stages. Pulmonary angiography is performed as part of the preoperative assessment. The management of CPE-PH is multidisciplinary. It requires collaboration between experts from different medical and surgical disciplines. Patients must be evaluated in an expert center (14, 15). The therapeutic choice depends on the location of the vascular obstruction, the severity of pulmonary hypertension assessed by right heart catheterization (in particular the value of PVR), and the presence of comorbid factors. Thus, the treatment is adapted to each patient. Depending on the location of the lesions, some patients may benefit from the successive combination of different therapeutic options, combined therapy (surgery, interventional treatment and drug treatment) (Figure 2, 3). Surgical treatment consists of pulmonary endarterectomy which constitutes the standard treatment when the lesions of the pulmonary arteries are accessible to surgery (proximal obstruction) (Figure 4). Distal obstruction is responsible for

persistent pulmonary hypertension, the leading cause of perioperative mortality (16). It is recognized as a major cause of poor short- and long-term prognosis (7). It should constitute a contraindication to pulmonary endarterectomy.

The aim of pulmonary endarterectomy is to improve pulmonary hemodynamics, exercise capacity, relieve symptoms and improve survival (17). A history of thromboembolism (pulmonary embolism and/or deep vein thrombosis), angiographic lesions located in the proximal or lobar pulmonary arteries, a good correlation between anatomical obstruction and RAP as well as the development of bronchial collateral circulation would be indicators of a favorable prognosis of pulmonary endarterectomy (16). The 5-year survival rate ranges from 74–89% (18).

Interventional treatment or balloon pulmonary angioplasty, percutaneously, it dilates small pulmonary arteries which cannot be reached by surgery. It is indicated in patients with inoperable forms (due to a distal location of the lesions or in patients with residual pulmonary hypertension after surgery. Japanese teams (19,20) studied the effectiveness of this therapeutic option, described in 2001 (21). The results were surprising in showing a hemodynamic (decrease in pulmonary arteries resistance) and functional (TM6 and NYHA) benefit with a mortality of less than 4%.

Medical treatment is used either alone or most often in combination with pulmonary angioplasty, as well as in patients with residual pulmonary hypertension after surgery. Several drugs have had marketing authorization, with a different mechanism of action but whose effect is synergistic: riociguat, bosentan, ambrisentan, tadalafil, sildenafil, subcutaneous treprostinil, intravenous epoprostenol. Two randomized controlled studies evaluated the hemodynamic and functional benefits in these patients after 16 weeks of treatment with bosentan (BENEFIT study) and riociguat (CHEST-1 study). The BENEFIT study (22) was unable to demonstrate any benefit on functional status despite an improvement in pulmonary hemodynamics. The CHEST-1 study (24), for its part, showed a hemodynamic and functional benefit (TM6 and NYHA class). Riociguat, a pulmonary vasodilator directly activating soluble guanylate cyclase (GCs) by a means different from that of NO and by increasing the sensitivity of GCs to NO, is the first drug to have shown positive hemodynamic and functional results in CPE-PH (24). Lung transplantation is considered in the event of failure of different therapies. The 5-year survival rate for lung and cardiopulmonary transplants performed in the setting of pulmonary hypertension is approximately greater than 50% (23). Anticoagulant treatment is continued when there is residual PH or when the patient is inoperable. The progression of the disease remains better compared to idiopathic PAH.

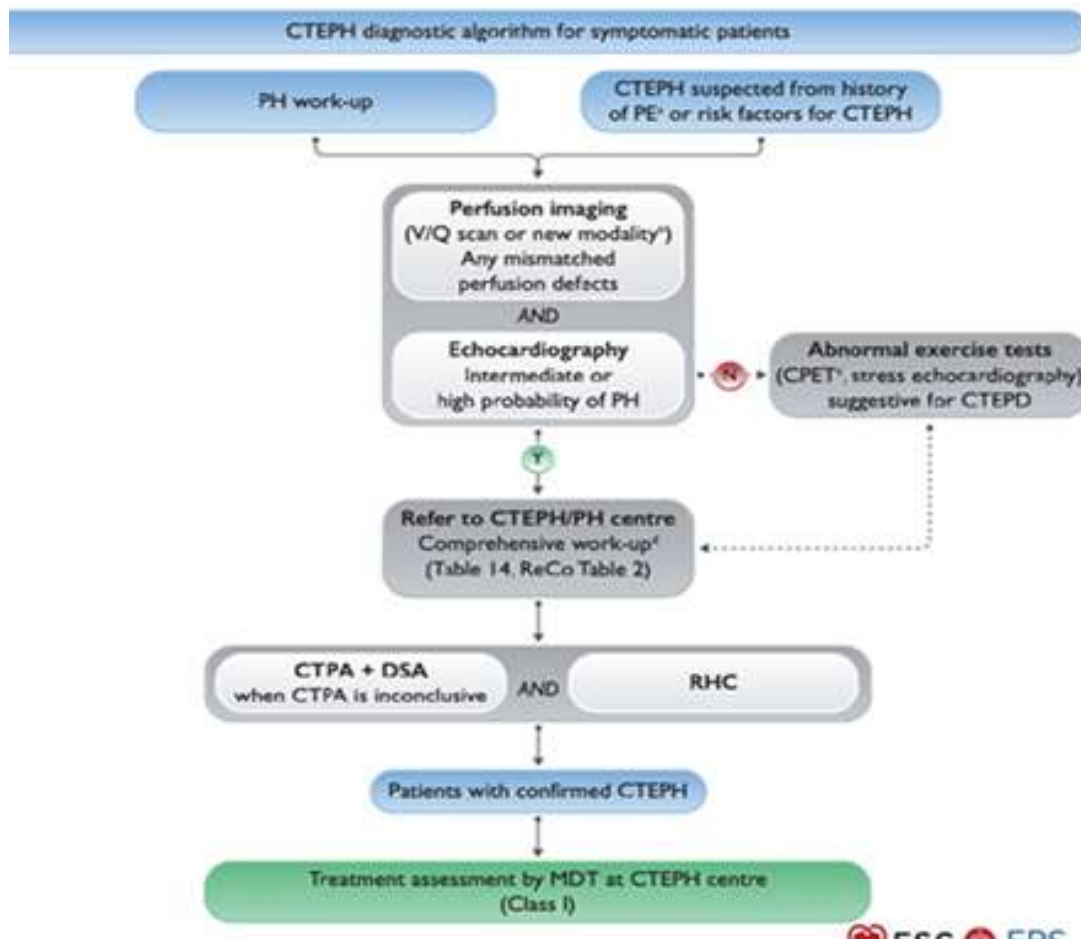


Fig 1: Diagnostic algorithm for CPE-PH (1)

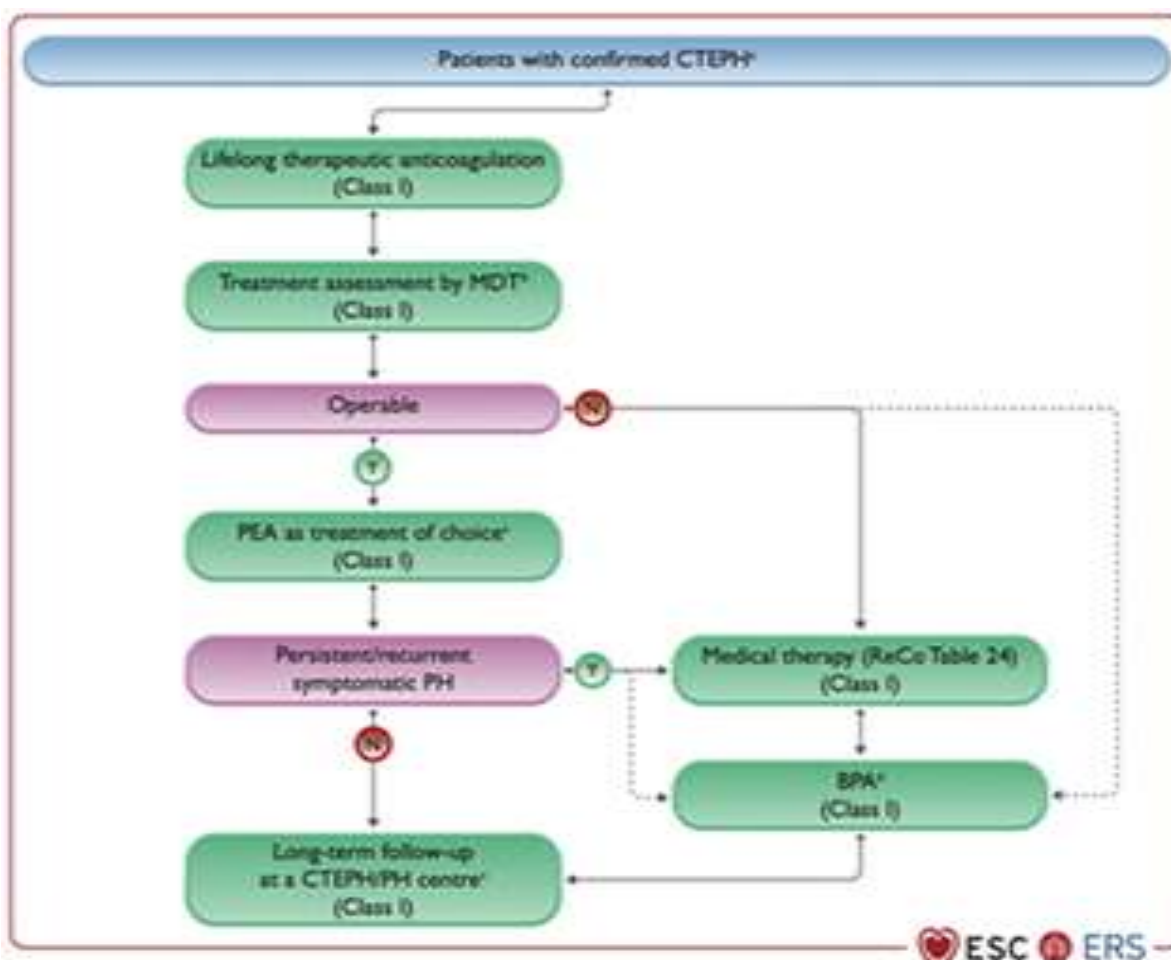


Figure 2: Algorithm for supporting CPE-PH (1)

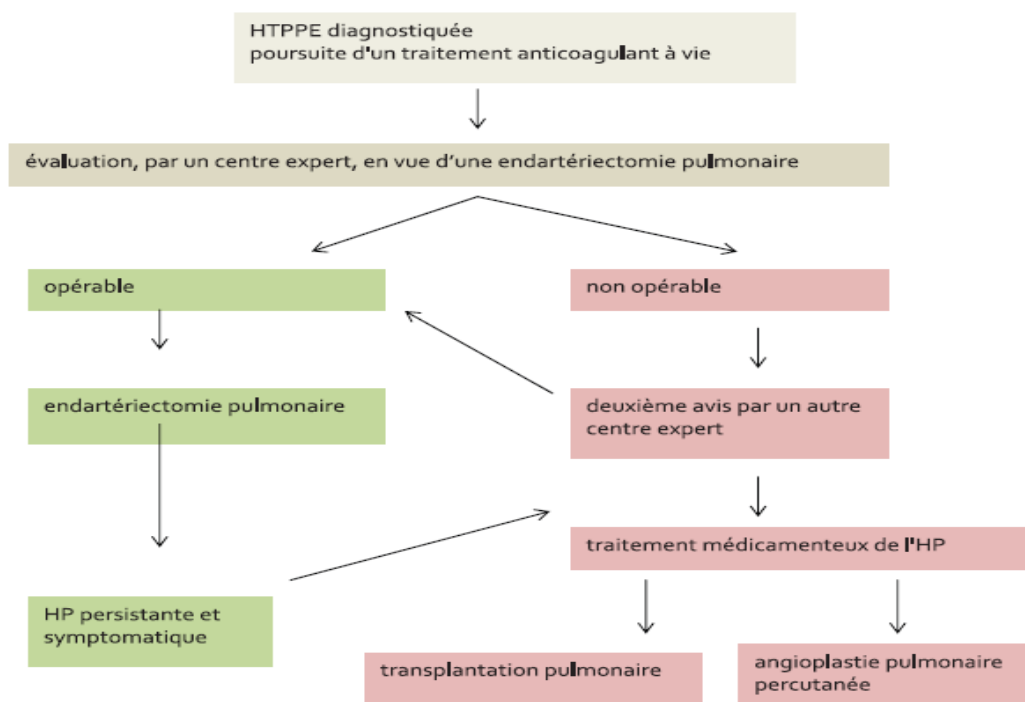


Figure 3: Algorithm for supporting HTP-PEC (1)

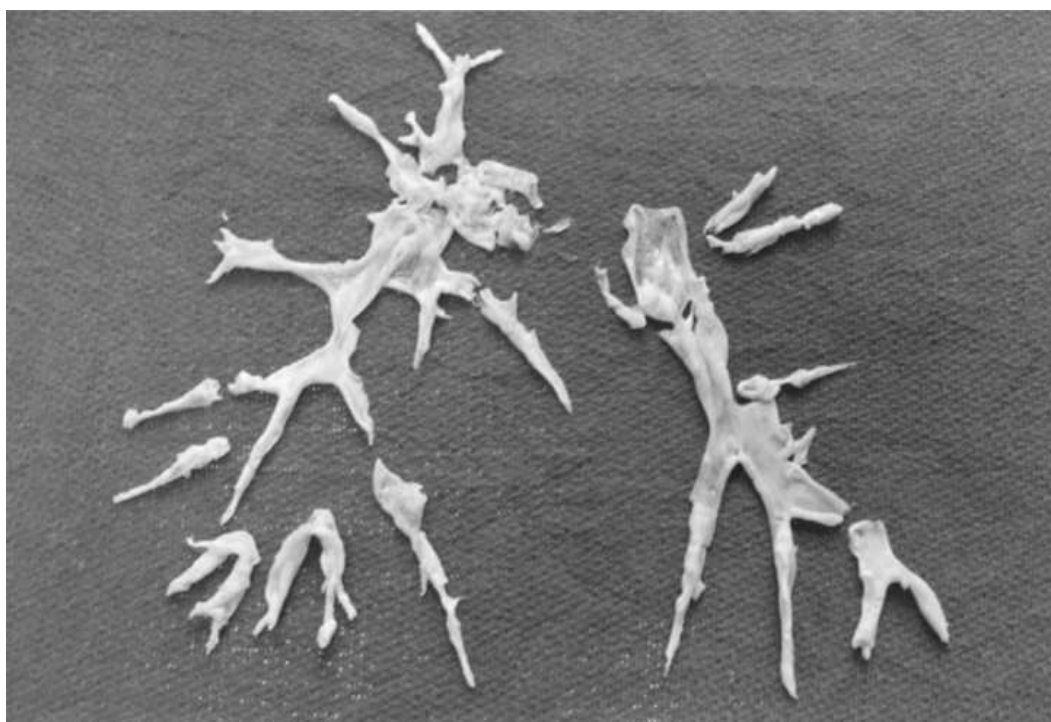


Figure 4: Pulmonary endarterectomy

Conclusion


Chronic postembolic PH is potentially curable. The immediate and persistent benefit can dramatically change the patient's quality of life. This surgical treatment requires in-depth knowledge and skills and involves a multidisciplinary team. The experience of the center is decisive for the success of this surgery. Progress must still be made in screening, in diagnostic techniques (notably in non-invasive imaging and the detection of distal arteriopathy), as well as in the determination of operative risk. These improvements will increase the survival rate of patients undergoing pulmonary endarterectomy.

References

1. Humbert M, Kovacs G, Hoeper MM, et al. 2022 ESC/ERS Guidelines for the diagnosis and treatment of pulmonary hypertension. Eur Respir J 2022;2200879.
2. Bonderman D et al., Risk factors for chronic thromboembolic pulmonary hypertension. Eur respir J 2009; 33:325-31)
3. Rev Mal Respi Actual 2009; 1:241-244
4. LANG IM, KLEPETKO W. Chronic thromboembolic pulmonary hypertension: an updated review. Curr Opin Cardiol, 2008; 23:555-559.

5. CONDLIFFE R, KIELY DG, GIBBS JS et al. Prognosis and aetiological factors in chronic thromboembolic pulmonary hypertension. *Eur Respir*, 2009; J 33: 332-338.
6. PENGO V, LENSING AW, PRINS MH et al. Incidence of chronic thromboembolic pulmonary hypertension after pulmonary embolism. *N Engl J Med*, 2004; 350: 2257-2264.
7. [7] Riedel M, Stanek V, Widimsky J, Prerovsky I. Long-term follow-up of patients with pulmonary thromboembolism. Late prognosis and evolution of hemodynamic and respiratory data. *Chest* 1982;81:151-8
8. Lang IM. Chronic thromboembolic pulmonary hypertension – not so rare after all. *N Engl J Med* 2004;350:2236-8.
9. *Rev Mal Respi Actual* 2009; 1:241-244
10. HOEPER MM, BARBERA JA, CHANNICK RN et al. Diagnosis, assessment, and treatment of non-pulmonary arterial hypertension pulmonary hypertension. *J Am Coll Cardiol*, 2009; 54: S85-S96.
11. Dartevelle P et al, surgical treatment of chronic pulmonary thromboembolic disease. *Medical Press* 2005; 34:1475-86
12. Jais X et al, Postembolic pulmonary hypertension. *Rev Mal Respi*. 2007; 24 (4Pt 1): 497-508
13. Hoepfer MM et al. Chronic thromboembolic pulmonary hypertension. *Traffic* 2006; 113: 2011-20
14. Wilkens H, Lang I, Behr J, Berghaus T, Grohe C, Guth S, et al. Chronic thromboembolic pulmonary hypertension (CTEPH): updated Recommendations of the Cologne Consensus Conference 2011. *Int J Cardiol* 2011;154(Suppl 1):S54-60.
15. Kim NH, Delcroix M, Jenkins DP, Channick R, Dartevelle P, Jansa P, et al. Chronic thromboembolic pulmonary hypertension. *J Am Coll Cardiol* 2013;62(25 Suppl):D92-9.
16. Dartevelle P, Fadel E, Chapelier A, Mussot S, Cerrina J, Leroy-Ladurie F, et al. Surgical treatment of post-embolic pulmonary hypertension. *Rev Pneumol Clin* 2004;60:124-34.
17. Hoepfer MM, Barberà JA, Channick RN, Hassoun PM, Lang IM, Manes A, et al. Diagnosis, assessment, and treatment of non-pulmonary arterial hypertension. *J Am Coll Cardiol* 2009;54(1 Suppl):S85-96.
18. Rahnnavardi M, Yan TD, Cao C, Vallety MP, Bannon PG, Wilson MK, et al. Pulmonary thromboendarterectomy for chronic thromboembolic pulmonary hypertension: a systematic review. *Ann Thorac Cardiovasc Surg* 2011;17:435-45.
19. Kataoka M, Inami T, Hayashida K, Shimura N, Ishiguro H, Abe T, et al. Percutaneous transluminal pulmonary angioplasty for the treatment of chronic thromboembolic pulmonary hypertension. *Circ Cardiovasc Interv* 2012;5:756-62.
20. Mizoguchi H, Ogawa A, Munemasa M, Mikouchi H, Ito H, Matsubara H. Refined balloon pulmonary angioplasty for inoperable patients with chronic thromboembolic pulmonary hypertension. *Circ Cardiovasc Interv* 2012;5:748-55.
21. Feinstein JA, Goldhaber SZ, Lock JE, Fern-dandes SM, Landzberg MJ. Balloon pulmonary angioplasty for treatment of chronic thromboembolic pulmonary hypertension. *Circulation* 2001;03:10-3.
22. Jais X, D'Armini AM, Jansa P, Torbicki A, Delcroix M, Ghofrani HA, et al. Bosentan for treatment of inoperable chronic thromboembolic pulmonary hypertension: BENEFiT (Bosentan Effects in inOperable Forms of chronic Thromboembolic pulmonary hypertension), a randomized, placebo-controlled trial. *J Am Coll Cardiol* 2008;52:2127-34.
23. Christie JD, Edwards LB, Aurora P, Dobbels F, Kirk R, Rahmel AO, et al. The Registry of the International Society for Heart and Lung Transplantation: Twenty-sixth Official Adult Lung and Heart-Lung Transplantation Report. *J Heart Lung Transplant* 2009;28:1031-49.
24. Ghofrani HA, D'Armini AM, Grimminger F, Hoepfer MM, Jansa P, Kim NH, et al. Riociguat for the treatment of chronic thromboembolic pulmonary hypertension. *N Engl J Med* 2013;369:319-29.

Copyright (c) 2024 The copyright to the submitted manuscript is held by the Author, who grants the Clinical Medicine and Health Research Journal a nonexclusive license to use, reproduce, and distribute the work, including for commercial purposes.

 This work is licensed under a [Creative Commons Attribution 4.0 International License](https://creativecommons.org/licenses/by/4.0/)